


THE NEW FACE OF
Aesthetics



AACD

THE AACD MONOGRAPH


A supplement to a
Marketing Media publication

Indirect Restorations: Enhanced Aesthetics Using All-Ceramic Treatment Options

Larry Rosenthal, DDS* • Jon Marashi, DDS*

Porcelain laminate veneers have revolutionized aesthetic dentistry, allowing the delivery of natural-looking restorations with minimal tooth reduction. Veneers can be used to mask severely discolored substructures while maintaining natural translucency and light transmission. These restorations can be used to literally transform a patient's smile, enhancing his or her overall appearance and sense of self worth.

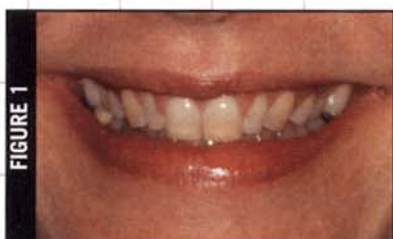

FIGURE 1
Preoperative evaluation indicated short clinical crowns, slight discoloration, and misaligned dentition.

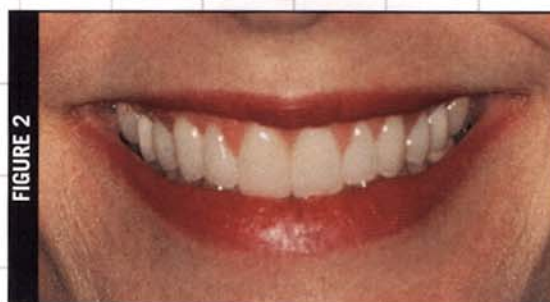

FIGURE 2
Postoperative appearance following restoration using porcelain laminate veneers demonstrates improved aesthetics and an enhanced smile.

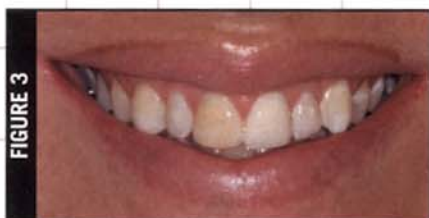

FIGURE 3
Preoperative smile demonstrates slight discoloration and rotation of the lateral incisors.

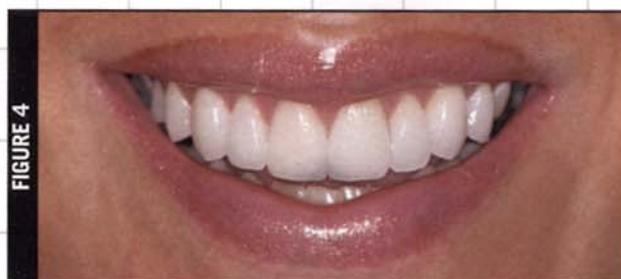

FIGURE 4
Patient satisfaction with the postoperative results was achieved following treatment with all-ceramic restorations to achieve a whiter, brighter appearance.

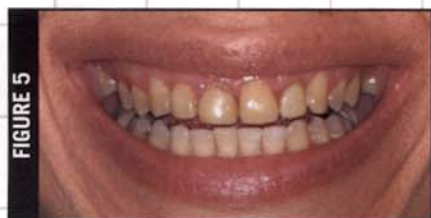

FIGURE 5
The patient was dissatisfied with her preoperative appearance and desired a brighter, more uniform smile.

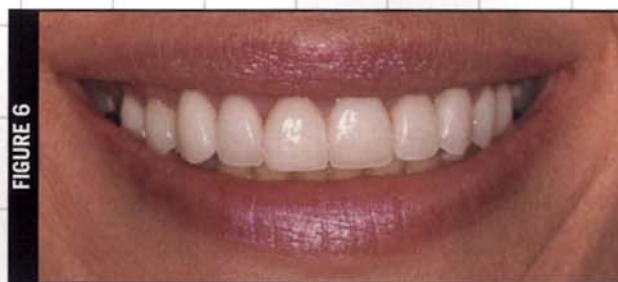

FIGURE 6
Postoperative aesthetics following placement of porcelain restorations achieved the expectations of the patient.