

DENTAL TRIBUNE

The World's Dental Newspaper · U.S. Edition

JUNE 30-JULY 6, 2008

www.dental-tribune.com

VOL. 3, No. 25

Inside this week

Maryland to boost dental spending

Public pressure over the death of Deamonte Driver has prompted Maryland to step up its spending on dental health care. **Page 3**

IACA to meet in Orlando


Hundreds of dentists and their office teams from opposite sides of the globe will be attending the IACA's fourth annual meeting in Orlando at the Dolphin and Swan Resort at Walt Disney World from July 30 to Aug. 2. **Page 4**

Advancing to the next level

Every dentist has the potential to turn a good practice into a great practice. It's challenging, but it can be done. **Page 6**

Clear the way for completion

Reaching new heights



Badge pick-up line on the meeting's first day.

Photos: Joanna N. Farber

By Joanna N. Farber, Managing Editor

“**A**im High” was the theme of the AAO's 108th Annual Session this year that took place from May 16-20. And it couldn't have been more appropriate, consid-

ering its location in the mile-high city of Denver.

Prior to the meeting's start, AAO President William C. Gaylord, DDS, MSD, said, “This is your yearly opportunity for learning about the state of the science and art of the

orthodontic specialty, and for fellowship with your colleagues.” Those words held true: Though this year's attendance numbers didn't break last year's — only 12,475 were there according to the AAO; last year's *See Reaching, Page 2*

DENTAL TRIBUNE | JUNE 30-JULY 6, 2008

Clinical 13

Patient 3

Restoration by Dr. Marashi

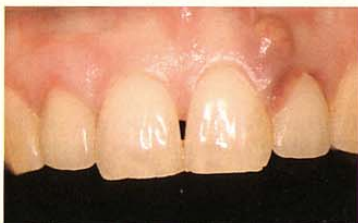

Fig. 3a: Endodontic abscess with buccal fistula over tooth No. 10.

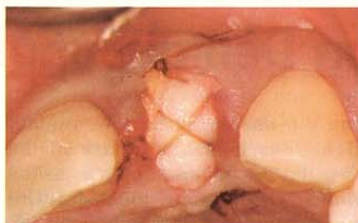


Fig. 3c: Crisscross overlay suture secures interpositional connective tissue graft over crest.

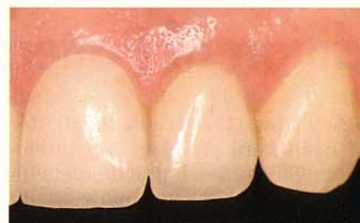

Fig. 3d: Ideal soft tissue esthetics achieved.

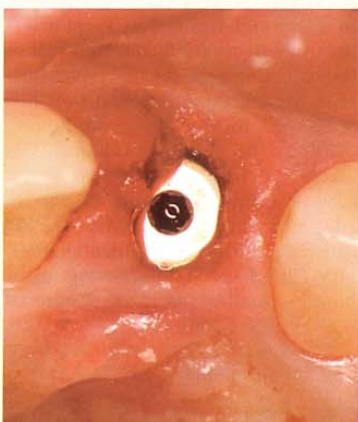

Fig. 3b: Immediate implant placement following socket degranulation and detoxification.

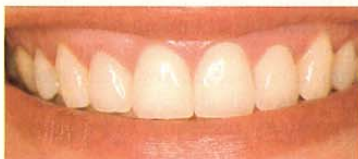

Fig. 3f: Cosmetic dentistry included anterior porcelain veneers (restoration by Dr. Jon Marashi).

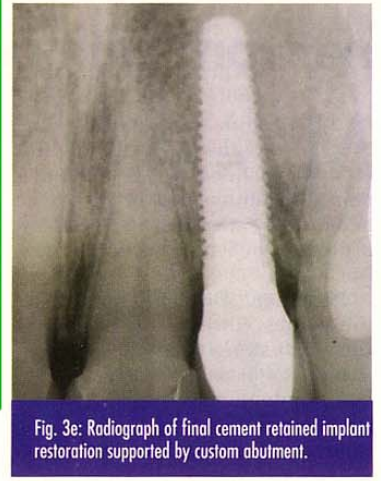


Fig. 3e: Radiograph of final cement retained implant restoration supported by custom abutment.

AD

Composite Finishing & Polishing Made Easy

Finishing & Polishing

Designed for easy, fast & safe contouring, finishing & polishing of all microfilled & hybrid composites.

- Flexible ultra-thin disks allowing easier access to interproximal areas
- No metal center eliminates gouging & discoloration
- Double sided - Disposable - 4 grit choices - 2 sizes